



Epiploic appendagitis : a case report

Appendagite épiploïque : à propos d'un cas

Anja Holinoro Randriamarolahy¹, Patricia Alice Razafindrahova¹, Marina Parfaite Hajamihamina², Andriamiambola Irène Rakotoniaina³, Ahmad Ahmad⁴

Correspondence

Patricia Alice Razafindrahova

Courriel : rpatricia_alice@yahoo.fr

Résumé

L'appendagite épiploïque est une pathologie caractérisée par l'ischémie et l'inflammation de l'appendice épiploïque, pouvant occasionner les douleurs abdominales sévères. Elle est relativement rare. Dans cet article, nous rapportons un cas clinique d'un homme de 45 ans admis pour une douleur localisée à la fosse iliaque gauche. L'examen physique a révélé une sensibilité abdominale au rebond. Le scanner a montré une infiltration graisseuse à la jonction colosigmoïdienne sous la forme d'une image graisseuse ovoïde entourée d'une hyperdensité périphérique, évocatrice d'une appendagite épiploïque dont l'évolution a été favorable sous traitement médical combinant les anti-inflammatoires non stéroïdiens et les antibiotiques.

Mots-clés: douleur abdominale aigue, appendagite épiploïque, scanner

<https://dx.doi.org/10.4314/aamed.v16i1.15>

Reçu le 26 juillet 2022

Accepté le 7 novembre 2022

1 Medical Imaging Department Teaching Hospital Mitsinjo Betanimena Toliara, Madagascar

2 Surgery Department Teaching Hospital Mitsinjo Betanimena Toliara, Madagascar

3 Laboratory Department Teaching Hospital Mitsinjo Betanimena Toliara, Madagascar

4 Medical Imaging Department Teaching Hospital -JRA Antananarivo, Madagascar

Summary

Epiploic appendagitis is a condition characterized by the ischemia and inflammation of the epiploic appendices of the colon that, can cause severe abdominal pain. It's relatively rare.

In the present article, we describe the clinical case of a 45-year-old man who was admitted with localized pain in the left iliac fossa. Physical examination revealed rebound tenderness. CT scan showed fat infiltration at the colosigmoid junction in the form of an ovoid fat image surrounded by peripheral hyperdensity, suggestive of epiploic appendagitis. The evolution was favorable under medical treatment combining nonsteroidal anti-inflammatory drugs and antibiotics.

Keywords: Acute abdominal pain, epiploic appendagitis, CT scan

Received: July 26th, 2022

Accepted: November 7th, 2022

Introduction

Epiploic appendagitis is one of the causes of acute abdominal pain (1). Epiploic appendagitis is a rare, self-limited condition characterized by the ischemia and inflammation of the epiploic appendages. It is mostly manifested as a localized, severe pain, usually in the right or left lower quadrant and it can mimic acute diverticulitis or appendicitis (2). Its diagnosis is difficult to retain by clinical approach alone. Imaging, in particular the CT scan, makes it possible to make the diagnosis, as illustrated by the present case.

Clinical observation

A 45-year-old man was admitted to the emergency room for pain in the left iliac fossa evolving for 3 days with the notion of fever, not yielding under antispasmodic. This pain was not accompanied by transit disorder or urinary signs. On arrival, the patient was afebrile and abdominal palpation revealed localized pain with guarding in the left iliac fossa. The biological assessment showed a moderate elevation of CRP at 12mg/L, a slight leukocytosis with neutrophilic polymorphonuclear at 11×10^9 cells per liter.

with a discreet normochromic normocytic anemia. An ultrasound was performed but the result was not satisfactory.

The suspicion of diverticulitis motivated the request for an abdominal CT scan. It showed fat infiltration at the colosigmoid junction in the form of an ovoid fat image surrounded by peripheral hyperdensity, suggestive of epiploic appendagitis (figure 1). Mesenteric fat planes surrounding the lesion were increased in density. The lesion showed peripheral contrast enhancement. A diagnosis of epiploic appendagitis was made according CT scan. Medical treatment was instituted combining nonsteroidal anti-inflammatory drugs and antibiotics. Good clinical evolution allowed the patient to be discharged on day 3. A control on day 7 showed a normal clinical and biological examination.

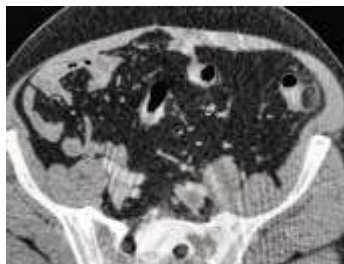


Figure 1. Axial section of an abdominal CT scan without injection of contrast showing an oval lesion of fat density and increased density in surrounding fat planes “ring sign” (arrow)

Discussion

Epiploic appendagitis is secondary to either torsion or spontaneous venous thrombosis of the

omental appendix, causing inflammation or ischemic infarction (3).

Its average age of onset is 40 years, the sex ratio close to 1 with a slight male predominance (4-5). The clinical manifestation is usually localized pain in the lower quadrants. This pain is usually isolated but may be accompanied by fever, nausea, vomiting or transit disorders (3). The biological disturbances are not very marked, with a moderate elevation of CRP or a slight hyperleucocytosis (6). These data from the literature agree with the present case.

Epiploic appendagitis can sit all along the colon with a predominance at the sigmoid level. Depending on its location, clinical signs suggest diverticulitis, appendicitis, cholecystitis or pancreatitis (7).

The typical appearance on the scanner makes it possible to make the diagnosis and thus avoids unnecessary surgery. This is a juxta-colic fatty density lesion with pathognomonic “ring sign” peripheral hyperdensity. Peripheral enhancement can be noted on an injected CT scan. Sometimes, a central hyperdensity corresponding to venous thrombosis is found (3,8). In a radiologic series, this pathology represented respectively 2.3 % and 1 % of patients explored on CT for diverticulitis and ileocecal appendicitis (9). Without a CT scan, ultrasound can also evoke it by showing a hyperechoic, non-compressible superficial oval mass opposite the painful area, surrounded by a hypoechoic and avascular halo on Doppler (3,5).

The treatment is medical. Nevertheless, surgical resection can be performed in case of the persistence of signs or in case of complications (9-10).

Conclusion

Localized acute abdominal pain without associated signs or significant biological disturbances should indicate imaging examinations in order to rule out epiploic appendagitis, which requires medical management.

Conflict of interest: The authors declare that they have no conflict of interest.



Contribution for authors: All authors contribute equally to this manuscript and approved the final as well as the revised version.

References

1. Slaiki S, Afdil M, El Bouhaddouti H, Benjelloun EB, Ousadden A, Ait Taleb K, *et al.* Appendagite épiploïque : cause rare d'abdomen aigu. *Pan Afr Med J* 2020; **36** : 149.
2. Singh AK, Gervais DA, Hahn PF, Sagar P, Mueller PR, Novelline RA. Acute epiploic appendagitis and its mimics. *Radiographics* 2005; **25**: 1521-1534.
3. Giannis D, Matenoglou E, Sidiropoulou MS, Papalampros A, Schmitz R, Felekouras E, Moris D. Epiploic appendagitis: pathogenesis, clinical findings and imaging clues of a misdiagnosed mimicker. *Ann Transl Med* 2019; **7**(24): 814.
4. Bonnefoy S, Corberand D, Sinayoko L, Harnois F, Mennercier D, Thiolet C. Appendagite épiploïque primitive : à propos d'un cas. *Gastroentérologie Clinique et Biologique* 2008 ; **32** : 1092-1094.
5. Singh AK, Gervais DA, Hahn PF, Sagar P, Mueller PR, Novelline RA. Acute epiploic appendagitis and its mimics. *Radiographics* 2005; **25**: 1521-1534.
6. Cigdem Oztunali, Taylan Kara. Radiologic findings of epiploic appendagitis. *Med Ultrason* 2013; **15**: 71-72.
7. Gaur S, Jawahar RP, Prasad R, Prbakaran M. Epiploic appendagitis - a rare cause of acute lower abdominal pain. *Radiol Case Rep* 2021; **16**: 1144-1147.
8. Almeida AT, Melão L, Viamonte B, Cunha R, Pereira JM. Epiploic appendagitis: an entity frequently unknown to clinicians-diagnostic imaging, pitfalls, and look-alikes. *Am J Roentgenol* 2009; **193**: 1243-1251.
9. Daghfous A, Bouzaïdi K, Ayari H, Yahmadi A, Zoghlemi A, Marhoul LR. Apport de l'imagerie dans le diagnostic des appendagites épiploïques. *Rev Med Interne* 2014; **35** (9): 565-569.
10. Akubudike J E, Egigba O F, Kobalava B. Epiploic Appendagitis: A Commonly Overlooked Differential of Acute Abdominal Pain. *Cureus* 2021 ; **13**(1): e12807. DOI 10.7759/cureus.12807.

Voici comment citer cet article : Randriamarolahy AH, Razafindrahova PA, Hajamihamina MP, Rakotoniaina AI, Ahmad A. Epiploic appendagitis : a case report. *Ann Afr Med* 2022; **16** (1): e4998-e5000. <https://dx.doi.org/10.4314/aamed.v16i1.15>