



Congenital myasthenic syndrome due to homozygous mutation of the cholinergic receptor nicotinic epsilon subunit in a Moroccan child

Syndrome myasthénique congénital due à une mutation homozygote de la sous-unité epsilon du récepteur cholinergique nicotinique chez un enfant marocain

Mohammed Abdoh Rafai^{1,2}, Malika Berrada¹,
Bouchra El Moutawakil^{1,3}, Hicham El Otmani^{1,3},
Hind Dehbi³

Correspondance

Mohammed Abdoh Rafai
Service de neurologie et d'explorations
neurophysiologiques cliniques, CHU IBN
ROCHD de Casablanca 1, Rue des Hôpitaux,
20000, Casablanca, Maroc
Mobile : + 212 6 61 66 88 24
Courriel : neuroblanca@gmail.com

Résumé

Les syndromes myasthéniques congénitaux sont des troubles neuromusculaires génétiquement transmis. Nous rapportons ici le cas d'un garçon de 10 ans, suivi pour une ophtalmoparésie, un ptosis et une fatigabilité évoluant depuis la petite enfance. L'électroneuromyogramme a montré un décrétement à la stimulation répétitive à 3 Hz et les tests génétiques ont identifié une mutation de type c.1293ins G au niveau de l'exon 12 de la sous unité epsilon du récepteur cholinergique nicotinique. Sous les inhibiteurs des cholinestérases, une nette amélioration clinique, a été observée. Cette pathologie potentiellement sensible aux médicaments souligne l'intérêt d'un diagnostic précoce afin d'éviter ses complications mortelles.

Mots-clés : congénitale, génétique, myasthénie, manifestations cliniques

Reçu le 19 août 2021

Accepté le 10 janvier 2022

<https://dx.doi.org/10.4314/aamed.v15i2.10>

1 Service de Neurologie - Explorations Neurophysiologiques Cliniques, CHU Ibn Rochd, Quartier des Hôpitaux, 20000, Casablanca, Maroc

2 Laboratoire De Recherche Sur les Maladies du Système nerveux, Neurosensorielles et Handicap, Université Hassan II, Faculté de Médecine et de Pharmacie- Rue tarik Ibn Ziad, 20000, Casablanca, Maroc

3 Laboratory of Medical Genetics, Faculty of Medicine And Pharmacy Hassan II- Rue tarik Ibn Ziad, 20000-Casablanca, Morocco

Summary

Congenital myasthenic syndromes are genetically transmitted neuromuscular disorders. We report a case of 10-year-old, presented with early onset ophthalmoparesis, diurnal fluctuations of ptosis and fatigability. Electromyography showed a decremental response to 3-hertz repetitive nerve stimulation and genetic tests identified a mutation of c.1293ins G in exon 12 in cholinergic receptor nicotinic epsilon subunit. The patient was treated with cholinesterase inhibitors with significant improvement. This possibly drug-responsive disease emphasizes the need for an early and quick diagnosis to avoid fatal complications of this disease.

Keywords: congenital, genetic, myasthenic, clinical manifestations

Received: August 19th, 2021

Accepted: January 10th, 2022

Introduction

Congenital myasthenic syndromes (CMS) are a heterogenous group of early-onset genetically transmitted neuromuscular disorders, caused by mutations to proteins of the motor endplate (involved in this latter's organization, maintenance or function) (1-2). Understanding CMS genetic basis is an ongoing field. This possibly drug-responsive disease (as presented in our case) emphasizes the need for an early and quick diagnostic.

Case report

We report the case of a 10 years old, second child of first cousin's healthy parents. Since the first months of life, he presented ophthalmoparesis, diurnal fluctuations of ptosis, facial weakness, fatigability, difficulties running and climbing stairs. His sister presented similar symptoms and died at the age one following a respiratory distress. On examination, he had presented a marked bilateral ptosis (Figure 1a), almost complete ophthalmoparesis, axial weakness and positive Gower's sign. He had a lumbar hyperlordosis (Figure 1b) and flat feet (Figure 1c).

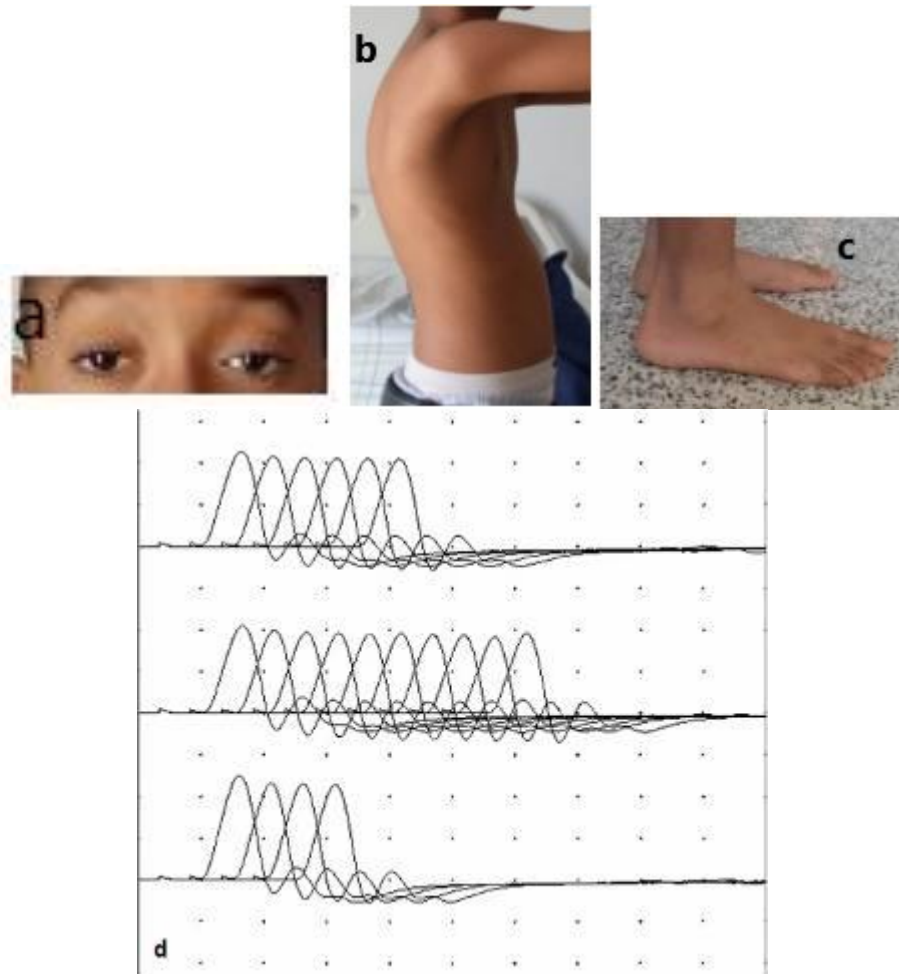


Figure 1. Clinical and Electromyography findings from the patient: Bilateral ptosis (1a), lumbar hyperlordosis (1b), flat feet (1c), Decremental response to 3-hertz repetitive nerve stimulation (1d)

He had no difficulty breathing and his cognitive development was normal. The family history and clinical presentation were consistent with the diagnostic of congenital myasthenic syndrome (CMS). Electromyography showed a decremental response to 3-hertz repetitive nerve stimulation of the following nerve-muscle pairs: facial nerve-nasalis, spinal accessory-trapezius, peroneal nerve-tibialis and ulnar nerve-abductor digiti minimi (Fig 1 d). Motor and sensory nerve conduction parameters were normal. Next-generation sequencing performed on serum samples obtained from both the child and parents identified a mutation of c.1293ins G in exon 12 in cholinergic receptor nicotinic epsilon subunit (CHRNE). Homozygous mutation in the patient and heterozygous in the parents were reported. The patient was treated with cholinesterase inhibitors (AChEI), pyridostigmine 60 mg strated at 1/4 tablet 3 times a day with a gradual

increase in dosage up to 3 tablets per day. He experienced significant improvement in both motor function and oculomotricity (myasthenic score at 78 % versus 50 % before treatment).

Discussion

CMSs are a rare genotypically and phenotypically heterogeneous group of neuromuscular disorders, which have in common an impaired neuromuscular transmission. The prevalence is estimated at 25–125/1000000 (3). Mutations in around 32 genes that encode proteins involved in this signaling pathway are known to cause CMSs. The CHRNE mutants account for over 50% of CMSs related to AChR (acetylcholine receptor) deficiency (2). One gene has been sequenced in our case (CHRNE gene). An increased prevalence of the CHRNE gene mutation has been described in patients

from the Maghreb, like in our patient (4). In a study of 23 families with CMS from Maghreb countries, the mutation c.1293insG was found in 60 % of these patients (4). The Type and severity of the clinical manifestations due to CHRNE mutations may vary considerably between affected families. Some patients may present with only ptosis whereas others may present with severe generalized myasthenia. Most patients present at birth with mildly progressive bulbar, respiratory, or generalized limb weakness with ptosis or ophthalmoplegia. Prematurely death may occur in infancy as a result of respiratory failure (2).

Due to its late expression during foetal life, AChR defect, as found in CHRNE CMS, has no consequence on maturation/development of neuromuscular apparatus. Hyperlordosis or hyperkyphosis were reported in patients carrying SCN4A, RAPSN or SYB1 mutations (2), but were also reported in our case without severe motor deficit. Foot deformities including pes cavus, planus or hammertoes observed in (SYT2, SLC25A1) (2), were present in our patient (pes planus). To the best of our knowledge, this association has never been reported. The Gowers sign presented by our patient can be found in a number of neuromuscular disorders including CMS (5). Patients with CMSs may deteriorate clinically in certain subtypes of CMS (COLQ, LAMB2, DOK7, MUSK, LRP4) (2,6). Molecular diagnosis is critical because incorrect treatment in CMS will be life-threatening (7).

Differential diagnoses that have to be excluded before diagnosing CMS in infants or children include transient neonatal myasthenia gravis, spinal muscular atrophy, congenital muscular dystrophy, congenital myotonic dystrophy-1, early onset mitochondrial disorders, congenital myopathy, Moebius syndrome and infantile botulism (2). In the absence of a clear cause for many CMS, clinical evaluation combined with electrophysiological analyses can help make the diagnosis for those who are not fortunate enough to have genetic analyses.

Conclusion

This case report allowed us to provide new insights into the genetic profile of a Moroccan patient with CMS and help with genetic counselling, diagnosis and treatment of CMS.

Conflict of interest

No Conflict of interest.

Acknowledgment

The authors thank the patient and his family for their collaboration.

Informed consent

Informed consent has been obtained from the patient and his parents.

Ethical approval

All procedures performed in studies involving human participants were in accordance with the ethical standards of the institutional and/or national research committee and with the 1964 Helsinki Declaration and its later amendments or comparable ethical standards.

Acknowledgment

The authors thank the patient and his family for their collaboration.

Contribution for authors

Rafai MA and Berrada M analyzed and interpreted the patient data, wrote the manuscript and were involved with the patient's care, B.EL Moutawakil and H.EL Otmani revised the manuscript and Dehbi reviewed the genetic aspect of the case report.

Funding

Not applicable.

References

1. Engel AG, Shen XM, Selcen D, Sine SM. Congenital myasthenic syndromes: pathogenesis, diagnosis, and treatment. *Lancet Neurol* 2015; **14**: 420-434.
2. Josef Finsterer. Congenital myasthenic syndromes. *Orphanet Journal of Rare Diseases* 2019; **14**: 57. <https://doi.org/10.1186/s13023-019-1025-5>
3. Abicht A, Müller J S, Lochmüller H. Congenital Myasthenic syndromes. 2003 may 9 [updated 2016 Jul 14]. In: Adam MP, Ardinger HH, Pagon RA, Wallace SE, Bean LJH, Mefford HC, Stephens K, Amemiya A, Ledbetter N, editors. GeneReviews® [internet]. Seattle (WA): University of Washington, Seattle; 1993-2017. Available on <http://www.ncbi.nlm.nih.gov/books/NBK1168/>.

4. Richard P, Gaudon K, Haddad H, Ben Ammar A, Genin E, Bauché S, *et al.* The CHRNE 1293insG founder mutation is a frequent cause of congenital myasthenia in North Africa. *Neurology* 2008; **71**: 1967-1972.
5. Espinoza IO, Reynoso C, Chavez G, Engel AG. Congenital myasthenic syndrome due to rapsyn deficiency: a case report with a new mutation and compound heterozygosity. *Medwave* 2019; **19** (5): e7645.
6. Beeson D, Hantäi D, Lochmüller H, Engel AG. 126th international workshop: congenital myasthenic syndromes, 24-26 September 2004, Naarden, the Netherlands. *Neuromuscul Disord.* 2005; **15**(7): 498-512. [PMID: 15951177].
7. An E, Vanhaesebrouck, David Beeson. The congenital myasthenic syndromes: expanding genetic and phenotypic spectrums and refining treatment strategies. *Current opinion Neurol.* 2019; **32**(5): 696-703. [PMID: 31361628]. doi: 10.1097/WCO.0000000000000736.

Cite this article as: Rafai MA, Berrada M, Moutawakil BE, Otmani HE, Dehbi H. Congenital myasthenic due to homozygous mutation of cholinergic receptor nicotinic epsilon subunit in a Moroccan child. *Ann Afr Med* 2022; **15** (2): e4614-e4617. <https://dx.doi.org/10.4314/aam.v15i2.10>